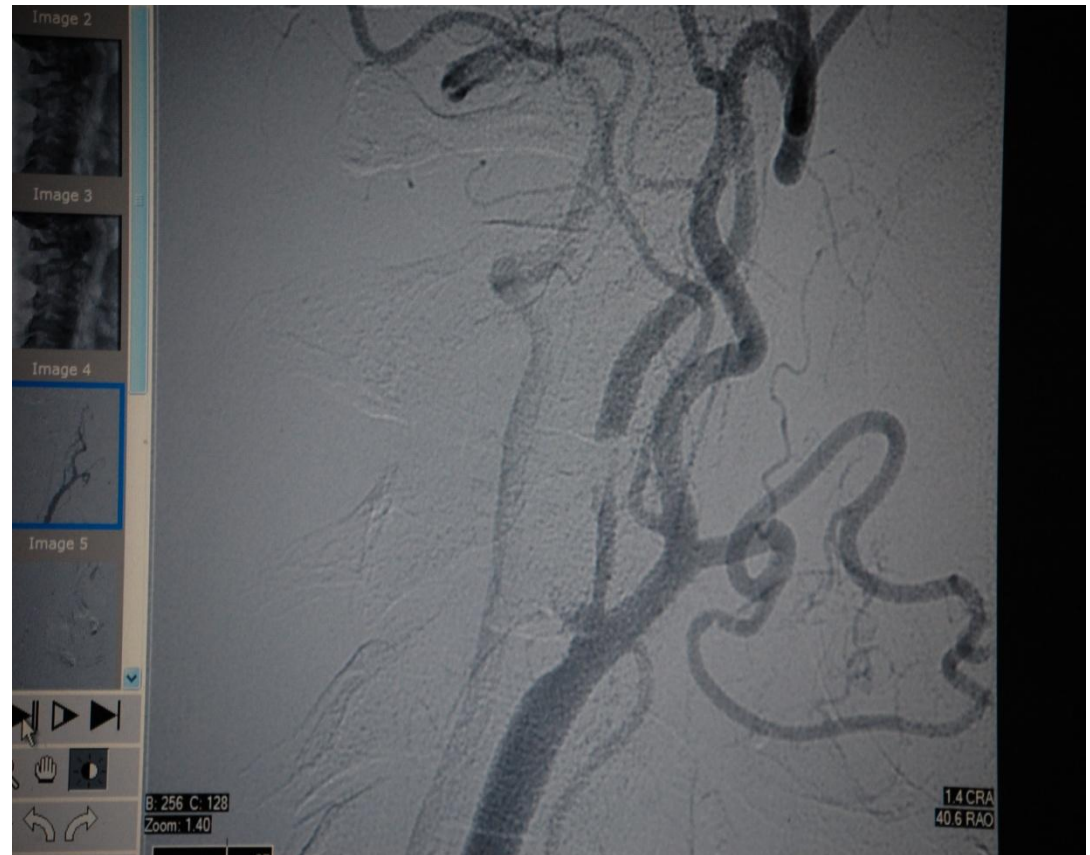


Dr. Vaqar Ali's RICA

MoMa Case

January 8, 2010

- Patient with High Cervical RICA String Sign lesion, Arch was Bovine and Type II .
- Nice cross filling from Contralateral side as well as Vertebrals.
- Treated RICA
- Use of MoMa alone for Proximal Protection



Dr. Vaqar Ali's RICA MoMa Case January 8, 2010

- Placed MoMa over Super Stiff Amplatz
- Inflated both ECA and CCA balloons
- Crossed lesion with a 0.014 BMW wire
- Pre-dilated, stented and Post-dilated with no issues.
- After three aspirations no debris was observed and both ECA and CCA balloons were deflated.
- Case was completed with no issues and a great result!

